

Developments in Collagen Cross-Linking Technique

by Mesha Tanna

Corneal Structure

The cornea has several important functions. Optically it acts as the outermost lens of the eye contributing to approximately two-thirds of the eye's total focusing power. In humans, this refractive power is approximately +43D which is the sum of the refractive power at the air-stroma interface of +49D minus the endothelium-aqueous power of +6D. Through its transparent properties, it transmits light through the lens to the retina. Additionally, and importantly, the cornea filters some of the damaging ultraviolet wavelengths of sunlight that would otherwise cause damage to the eye.¹

In humans, the average corneal diameter is 11.5mm vertically and 12mm horizontally with a thickness of 0.5-0.6mm in the centre and 0.6-0.8mm at the periphery.²

The human cornea is comprised of five layers: the epithelium, Bowman's layer, the stroma, Descemet's membrane and the endothelium.

1. The epithelium is stratified, squamous and non-keratinised comprising of a single layer of basal columnar cells which are attached to neighbouring basal cells and overlying wing cells by desmosomes. The surface area of the squamous surface cells is increased by microplicae and microvillae. Superficially these squamous cells desquamate after a lifespan of a few days into the overlying trilaminar

tear film and regenerate by multiplication in the basal layer.

2. Bowman's layer, 8-14 micrometres thick, is a thick acellular collagenous layer protecting the superficial layer of the stroma.

3. The stroma makes up 90% of corneal thickness comprised of regularly arranged collagen fibrils whose spacing is maintained by proteoglycan ground substance (chondroitin sulphate and keratan sulphate) with interspersed modified keratocytes. It consists of 200 layers of mainly type 1 collagen fibrils, each layer 1.5-2.5 micrometres.

4. The Descemet's membrane is composed of a fine lattice of mainly collagen IV fibrils serving as the basement membrane of the corneal endothelium. It varies between 5-20 micrometres depending on age. The anterior banded portion is produced in foetal life and the posterior portion is formed postnatally taking on a granular appearance produced by the endothelium.

5. The endothelium consists of a single layer of squamous hexagonal cells. Typically 5 micrometres in thickness, the cells are responsible for regulation of fluids and solute transport between the aqueous and the corneal stroma. The adult cell density is about 2500 cells/mm² and there is a progressive reduction in endothelial cell with age (0.6%

average per year) since, unlike the corneal epithelium, the endothelial cells do not regenerate. At a cell density of 500 cells/mm², corneal oedema develops and corneal transparency is reduced.

It has been assumed that the collagen fibrils cross the entire plane of the cornea before either fusing with collagen fibrils in the limbus or continuing into the sclera. The average fibril diameter remains constant across the cornea before rising sharply at the limbus and there is no change in diameter with stromal depth.³

Corneal Age-Related Changes

The cornea undergoes key structural changes with age. These include¹:

- Thickening of both the epithelial and endothelial basement membranes (Descemet's membrane)
- Decrease in nerve density in the sub-basal plexus, below the epithelium
- Decrease in the number of conjunctival keratocytes
- Loss of corneal endothelial cells

Figure 1 shows the major age-related changes in the cornea. Fluid accumulation leads to corneal oedema and loss of corneal transparency. This leads to bullous keratopathy featuring an opaque cornea and separation of the corneal epithelium from its underlying matrix, referred to as bullae. Both

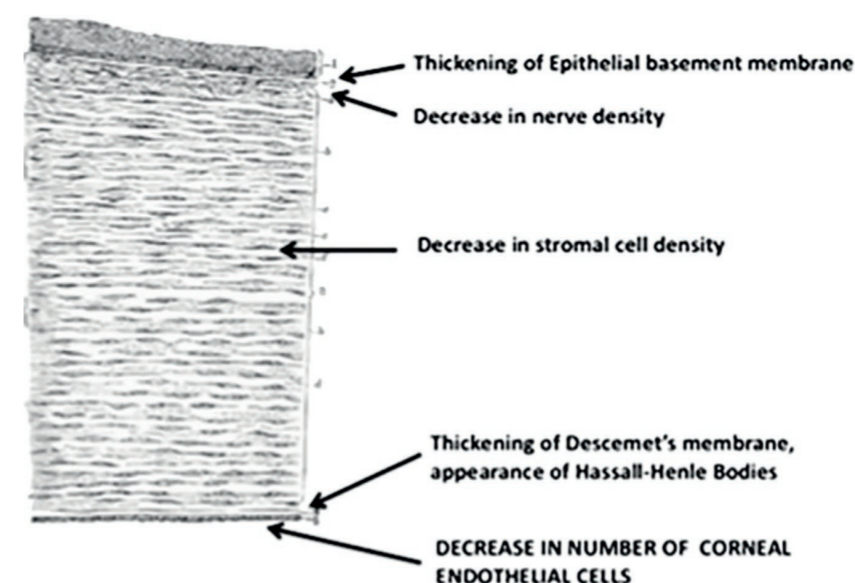


Fig 1 – Age-related changes in the cornea¹

causes of bullous keratopathy are both age-related: (1) Fuchs' endothelial corneal dystrophy and (2) iatrogenic endothelial damage due to cataract or other forms of surgery.

Fuchs' endothelial corneal dystrophy

This is characterised by progressive loss of endothelial cells, thickening of Descemet's membrane and by the development of mounds of extracellular material on Descemet's membrane, called guttae. Fuchs' endothelial corneal dystrophy is primarily a late-onset genetic disorder usually spanning over 10-20 years. When the number of endothelial cells becomes critically low, the cornea swells and causes loss of vision^{1,4}.

Dry Eye

Dry eye is a condition associated with a broad spectrum of ocular

symptoms, including burning, itching, redness, discomfort and ocular fatigue. Dry eye was defined by the Dry Eye Workshop (DEWS 2007a) as "a multi-factorial disease of the tears and ocular surface that results in symptoms of discomfort, visual disturbance and tear instability. It is accompanied by increased osmolarity of the tear film and inflammation of the ocular surface".⁵

In the general population (independent of surgery) epidemiologic studies identified prevalence rates ranging from 7% in the United States to 33% in Taiwan and Japan. Risk factors include advanced age, female gender, smoking, extreme heat or cold weather conditions, low relative humidity, use of video display terminals, refractive surgery, contact lens wear and certain medications.⁵

There are different sub-classifications of dry eye with the most prevalent being Evaporative Dry Eye (EDE), resulting from Meibomian Gland Dysfunction (MGD)⁶, a condition which is wholly unrelated to Laser Eye and Intraocular Lens surgery.

Changes include reduction in the number of meibomian glands and keratinisation of the gland ducts, gland dropout and composition changes of the meibum. The lacrimal gland undergoes inflammation and ductal fibrosis (especially in women) causing diminished levels and quality of secretion with age.

Infection

One infection that affects the cornea with age is Herpes Zoster Ophthalmicus (HZO) resulting from the activation of the varicella-zoster virus that lies dormant in nerve ganglia. HZO is defined as herpes zoster (HZ) within the ophthalmic division of the fifth cranial nerve (V) occurring typically in persons with zoster-associated pain of 30 days or longer, immunocompromised status, female gender and older age (≥ 50 years) at initial presentation. The most common presenting ophthalmic manifestations in HZO are keratitis, uveitis and conjunctivitis. The condition is also known as shingles with a painful rash in tissues mostly innervated by the trigeminal nerves shared by the skin around the eye as well as the ocular surface and its adnexa.^{1,7}

Ocular and Corneal Aberrations

Fujikado et al concluded that ocular higher-order aberrations, measured using a Hartmann-Shack aberrometer, increased with age especially after the age of fifty due to the increase of lenticular higher-order aberrations.⁸

It is not yet clear whether the changes of the aberrations with increasing age are due to changes in the cornea or to the internal optics of the eye, namely the posterior surface of the cornea and the crystalline lens.

Corneal Sensitivity

Using a Cochet-Bonnet aesthesiometer, corneal sensitivity was measured at five corneal regions in five different age groups.⁹ All regions of the cornea showed a faster reduction in sensitivity with age ($p < 0.001$). The strongest correlation between age and corneal sensitivity was for the centre of the cornea (-0.52), followed by nasal (-0.49), temporal (-0.48), inferior (-0.47) and superior (-0.46) regions of the cornea.

Corneal Curvature and Asphericity

Pentacam data from 3749 people were used to evaluate the effect of corneal curvature and asphericity over a 5 year period.¹⁰ K_{max} and K_{min} increased by 0.38 ± 1.95 diopters and 0.46 ± 1.97 diopters, respectively. According to the mean radius of sagittal curvature indices, the cornea steepened in the centre and flattened in the periphery. The increase in anterior and posterior asphericity was 0.15 ± 0.14 and 0.09 ± 0.14 , respectively (all $P < 0.001$). Women, compared to men, showed more change in K_{max} , K_{min} , and posterior asphericity (all $P < 0.001$) but not in anterior asphericity ($P = 0.937$).

Corneal Collagen Cross Linking

Cross linking occurs naturally with age in the cornea and in the

crystalline lens. The diameter of the cornea fibrils increases in diameter by 4.5% due to age-dependent glycolisation cross-linking. Crystallins with the lens increases in molecular weight and rigidity, secondary to age-related cross-linking.

Corneal collagen cross-linking (CXL) with riboflavin and ultraviolet A (UVA) is a technique to strengthen corneal tissue using riboflavin as a photosensitizer and UVA to increase the formation of intra- and inter-fibrillar covalent.¹¹ Treatment for advanced keratoconus can be limited since CXL at present can only be performed with corneal thickness greater than 400 micrometres due to concerns about the cytotoxic effect on the endothelium, crystalline lens and other intraocular tissues.

The use of riboflavin/UVA was adapted for corneal use in the mid-1990s when Seiler et al carried out a study to see the effects of keratoconus in diabetic patients. Manifest diabetes stiffens the cornea because of a glycolisation-mediated cross-linking that strengthens the collagen stroma.^{12,13} The goal was to create a similar cross-linking effect in non-diabetic patients using sugars activated by UV light. Spoerl et al¹⁴ were the first to investigate the use of riboflavin and UVA irradiation to achieve crosslinking of corneal collagen and significant increased stiffness of the cornea ($p < 0.05$) in porcine eyes.

In 2003, a clinical and experimental breakthrough was achieved by Wollensak et al¹⁵ when they reported on the clinical efficacy and biocompatibility of the riboflavin/UVA system in human corneas, which paved the

way for clinical trials.

The crosslinking effect is not distributed homogeneously over the corneal depth. The stiffening effect is concentrated in the anterior 200 to 300 μ m of the cornea due to the high absorption of UV light in this area. In 1998 the first keratoconus patients had cross linking.¹⁶

Crosslinking Technique and Procedure

There are two different collagen cross-linking methods: the chemical crosslinking uses solutions like glutaraldehyde, transglutaminase, genepin and nitroalcohol, and the photooxidative (also called physical) crosslinking uses light especially UV-light.¹⁷ The application of liquid cross linker to the curved cornea is not easy and the diffusion of the liquid cannot be controlled during application. Thus the photooxidative crosslinking is considered a safer application.¹⁸ It can be performed as treatment after epithelial debridement or transepithelial treatment (crosslinking without removal of the epithelium). The current technique uses riboflavin, the photosensitizing agent, which when exposed to UV-A light of wavelength 370nm, releases free radicals or reactive oxygen species into the surrounding stroma causing cross-link formation between the amino acids on the collagen chains at the intra- and interhelical levels resulting in an increase in collagen fibril diameter and also at the intermicrofibrillar level causing an increase in spacing between the collagen fibrils.^{13,19}

Treatment after Epithelial Debridement

The procedure involves scraping the central nine millimetres of cornea, measuring the baseline corneal thickness with an ultrasound pachymeter. 0.1% riboflavin solution is applied to the central cornea every 2 to 3 minutes over a 30 minute period to allow sufficient saturation of the stroma being careful not cause disruption to the limbal stem cells of the cornea. Following this, the exposed cornea is irradiated with UV-A light from a distance of 5cm from the cornea. The UV-A light illumination is calibrated at 365nm- 370nm providing an irradiance of $3\text{mW}/\text{cm}^2$. During the 30min of irradiation, riboflavin 0.1% drops may be applied to the cornea at 5min intervals to sustain the necessary concentration of the riboflavin. Intraoperative corneal thickness is measured during the procedure. Following the treatment a broad spectrum antibiotic is instilled and a bandage contact lens inserted for up to 5 days. Topical treatment of antibiotics and corticosteroids are prescribed to reduce the development of haze and postoperative inflammation. Regular post-operative visits should be scheduled to assess corneal healing, removal of the bandage contact lens and assess stability of the cornea.

Trans-epithelial Technique

The advantage to leaving the corneal epithelium intact is to reduce the patient's discomfort. Riboflavin does not readily penetrate the epithelium and hence to increase the absorption of riboflavin into the anterior stroma, drops containing preservatives, for example, benzalkonium chloride preoperatively or the use of

multiple applications of topical anaesthetic agent tetracaine 1% are used before the procedure to break the epithelial tight junctions. Another technique is causing a superficial epithelial trauma without complete epithelial debridement.²⁰ Corneal epithelium removal is an essential component of riboflavin-UVA crosslinking therapy to allow penetration of riboflavin into the corneal stroma. Inadequate stromal absorption of riboflavin may impair the efficacy of the crosslinking process.²⁰ In a study of fifty rabbits divided into 5 groups: UVA treatment with or without corneal epithelium, UVA/riboflavin treatment with or without corneal epithelium, and control without any treatment, the maximal stress and Young's modulus of cornea was found greatest in UVA/riboflavin and "epithelium-off" group which was 35.9% and 15.4% higher compared to the UVA/riboflavin and "epithelium-on" group, respectively ($P < 0.05$). Therefore, corneas without epithelium seem to benefit more from CXL.²¹ Using immunofluorescence microscopy in porcine corneas, it was found that the corneal epithelium reduces the effectiveness of CXL by preventing the penetration of the drug and not by limiting the UVA transmittance.²² Transepithelial CXL reduced the biomechanical effect by approximately one fifth compared with conventional crosslinking in a study by Wollensak and Iomdina.²³

Accelerated Corneal Collagen Cross Linking

Accelerated CXL significantly reduces exposure time while maintaining the same treatment

dose. Combining CXL with corneal laser surgery ideally necessitates a shorter treatment time. Based on the Bunsen-Roscoe law of reciprocity, having a constant radiant exposure of $5.4\text{ J}/\text{cm}^2$, accelerated CXL has been developed as an alternative treatment protocol with higher illumination intensity but shorter duration.¹⁹ This implies that the total energy delivered and amount of cross-linkage induced in a standard CXL session should be similar to irradiation at $9\text{ mW}/\text{cm}^2$ for 10 min, $15\text{ mW}/\text{cm}^2$ for 6 min, and $30\text{ mW}/\text{cm}^2$ for 3 min, with all ultimately delivering the same energy ($5.4\text{ J}/\text{cm}^2$).²⁴

Uses of Corneal Collagen Cross Linking

Studies demonstrate the use of CXL for corneal ectasias such as keratoconus and pellucid marginal degeneration. In addition to combining it with other treatments such as intra corneal ring segment implantation, it is used to treat infectious keratitis, bullous keratopathy and ulcerative keratitis.¹⁸

CXL advantages to increase the resistance of the cornea to enzymatic digestion and UVA to kill microbes, offers a role in the treatment of microbial keratitis. Studies have shown halting of corneal melting in the majority of patients preventing keratoplasty.²⁵⁻²⁷ Simultaneous topography-guided PRK and CXL can be used to improve vision, refraction and topography in keratoconus and keratectasia (mainly occurring after Laser in Situ Keratomileusis). Characteristics of keratectasia include progressive corneal thinning and steepening resulting in myopia, irregular astigmatism

and loss of corrected distance visual acuity.²⁸

Contraindications of Corneal Collagen Cross Linking

CXL should not be considered in the following cases¹³:

- Less than 400 micrometres corneal thickness after removal of the epithelium
- Patients with prior incisional refractive surgery (radial keratotomy or astigmatic keratotomy)
- Alterations within the corneal stroma post-CXL, particularly the contraction of the collagen lamellae, can cause the keratotomy incisions to rupture
- Central corneal opacities
- Severe dry eye which can hinder reepithelialisation
- Individuals who are pregnant/nursing
- Individuals with a systemic collagen vascular disease

Complications of Corneal Collagen Cross Linking

Risks include the formation of temporary corneal haze, permanent scars, endothelial damage, treatment failure, sterile infiltrates, bullous keratopathy and herpes reactivation.¹⁸ Keratitis can occur following CXL because of presence of an epithelial defect, use of soft bandage contact lens and topical corticosteroids in the immediate postoperative period. In cases of corneal infection after CXL, contact with the infectious agent likely has occurred during the early postoperative period rather than during surgery because CXL not only damages keratocytes but it also kills bacteria and

fungi. This advantageous effect allows CXL to be performed for infectious keratitis.

Bacterial keratitis, acanthamoeba keratitis, polymicrobial keratitis, herpetic keratitis, staphylococcus epidermidis keratitis and diffuse lamellar keratitis (stage 3), following treatment in a case of post-LASIK ectasia, have all been reported following CXL treatment.²⁹⁻³⁴

Mild-stromal haze occurs in virtually all eyes appearing at 2-6 weeks post-operatively. Post CXL haze sees an improvement in appearance after 6 months from treatment and usually requires minimal treatment with low dose steroid treatment or no treatment. The development of haze after CXL is considered greater in advanced keratoconus down to reduced corneal thickness and increase corneal curvature. This haze differs from the haze forming following PRK in stromal depth. Haze after PRK is strictly sub-epithelial whereas haze after CXL extends into the anterior stroma to approximately 60% depth, which corresponds to on average an absolute depth of 300µm.^{18,35} Steroid infiltrates have been reported in the early healing stages post operatively. With topical dexamethasone these typically resolve by four weeks. Treatment for atopic eye disease and prophylactic treatment for patients with previous herpetic disease prior to CXL can help to reduce infection, keratitis and corneal melting, which have been reported as complications following CXL.³⁵

Whilst the vast majority of keratoconic and post-refractive surgery ectasia cases are stabilised after CXL, progression of keratoectasia can occur. Raiskup

et al. reported stability in 99% of cases in a series of 241 eyes with >6 months of follow-up.³⁶ Koller et al. reported progression in 8 of 117 eyes (7.6%)³⁷. Advanced keratoconus with maximum keratometry values >58 D were risk factors with the greatest risk of progression.

The reliability of IOP after CXL decreased using Goldmann applanation tonometry, dynamic contour tonometry and the TonoPen XL and it resulted in overestimation of mean IOP. The mean (±SD) difference between IOP readings after and before CXL was +1.8 (3.5) mm Hg for DCT, +2.9 (6.1) mm Hg for GAT, and +3.1 (8.3) mm Hg for TP (P ≤ 0.002 for DCT versus GAT or TP). Since the results are less accurate and more variable, care should be taken when measuring IOP following CXL.³⁸

Future developments

There are now additional treatments that can be used in conjunction with CXL that can improve vision.³⁹ This is referred to as “CXL plus”

- Trans-epithelial phototherapeutic keratectomy (t-PTK) – epithelial removal using t-PTK during CXL results in better visual and refractive outcomes compared to mechanical debridement
- Topography-guided and other forms of photorefractive keratectomy (PRK) – this can be used in post-Lasik ectasia cases
- Intra-corneal ring segments
- Phakic intraocular lens implantation

Funding decisions are taken by local NHS bodies after considering the clinical effectiveness of

the procedure and whether it represents value for money for the NHS.

Whilst riboflavin/UVA CXL has been shown to be effective, other methodologies are currently under investigation. A recent study describes the use of Rose Bengal and green light as an alternative to CXL with riboflavin and UVA.⁴⁰ This technique may overcome some of the drawbacks of CXL including dehydration of the cornea, cytotoxicity to keratocytes and the high percentage of corneal thickness that must be treated to get the desired effect. Rocha et al. have reported a flash-linking process with UVA and polyvinylpyrrolidone, which may have the potential to crosslink the cornea photochemically within 30 seconds. Paik et al. have investigated the topical application of short-chain aliphatic beta-nitro alcohols. Without doubt other approaches and applications will become available over the next few years owing to the vast interest in this area of research.

References

1. Gipson, I.K. 2013, "Age-related changes and diseases of the ocular surface and cornea", *Investigative ophthalmology & visual science*, vol. 54, no. 14, pp. ORSF48.
2. Jack J Kanski J.J. *Clinical Ophthalmology A systemic approach*, 6th edition Butterworth-Heinemann; 2007
3. Meek, K.M. & Boote, C. 2004, "The organization of collagen in the corneal stroma", *Experimental Eye Research*, vol. 78, no. 3, pp. 503-512.
4. Elhalis, H., Azizi, B. & Jurkunas, U.V. 2010, "Fuchs Endothelial Corneal Dystrophy", *The Ocular Surface*, vol. 8, no. 4, pp. 173-184.
5. Gayton, J. 2009, "Etiology, prevalence, and treatment of dry eye disease", *Clinical Ophthalmology*, vol. 2009, pp. 405-412.
6. Lemp, M.A., Crews, L.A., Bron, A.J., Foulks, G.N. & Sullivan, B.D. 2012, "Distribution of Aqueous-Deficient and Evaporative Dry Eye in a Clinic-Based Patient Cohort: A Retrospective Study", *Cornea*, vol. 31, no. 5, pp. 472-478.
7. Tran, K.D., Falcone, M.M., Choi, D.S., Goldhardt, R., Karp, C.L., Davis, J.L. & Galor, A. 2016, "Epidemiology of Herpes Zoster Ophthalmicus", *Ophthalmology*, vol. 123, no. 7, pp. 1469-1475.
8. Fujikado, T., Kuroda, T., Ninomiya, S., Maeda, N., Tano, Y., Oshika, T., Hirohara, Y. & Mihashi, T. 2004, "Age-related changes in ocular and corneal aberrations", *American Journal of Ophthalmology*, vol. 138, no. 1, pp. 143-146.
9. Mirzajani, A., Khezri, F., Jafarzadehpour, E., Karimian, F. & Khabazkhoob, M. 2015, "Normal corneal sensitivity and its changes with age in Tehran, Iran: Age-related corneal sensitivity changes", *Clinical and Experimental Optometry*, vol. 98, no. 1, pp. 54-57.
10. Hashemi, H., Asgari, S., Emamian, M.H., Mehrvaran, S. & Fotouhi, A. 2015, "Age-Related Changes in Corneal Curvature and Shape: The Shahroud Eye Cohort Study", *Cornea*, vol. 34, no. 11, pp. 1456-1458.
11. Spadea, L. & Mencucci, R. 2011, "Corneal collagen cross-linking", *Ophthalmology*, vol. 118, no. 12, pp. 2520.e1-2520.e4.
12. Seiler, T., Huhle, S., Spoerl, E. & Kunath, H. 2000, "Manifest diabetes and keratoconus: A retrospective case-control study", *Graefes' Archive for Clinical and Experimental Ophthalmology*, vol. 238, no. 10, pp. 822-825.
13. Dahl, B.J., Spotts, E. & Truong, J.Q. 2012, "Corneal collagen cross-linking: an introduction and literature review", *Optometry (St. Louis, Mo.)*, vol. 83, no. 1, pp. 33-42.
14. Sporel E, Huhle M, Kasper M, Seiler T. Increased rigidity of the cornea caused by intrastromal crosslinking. *Ophthalmologie*. 1997;94(12):902-906
15. Wollensak G, Spoerl E, Seiler T. Increased resistance of riboflavin/ultraviolet-A treated cornea against enzymatic digestion. *Curr Eye Res*. 2004;29(1):35-40
16. Kohlhaas M, Spoerl E, Schilde T, et al. Biomechanical evidence of the distribution of cross-links in corneas treated with riboflavin and ultraviolet A light. *J Cataract Refract Surg* 2006; 32:279-283
17. Wollensak G, Spoerl E, Seiler T. Riboflavin/ultraviolet-A-induced collagen cross-linking for the treatment of keratoconus. *Am J Ophthalmol*. 2003;135(5):620-627.
18. Adel Alhayek Pei-Rong Lu 2015, "Corneal collagen crosslinking in keratoconus and other eye disease", *Journal of Ophthalmology*, vol. 8, no. 2, pp. 407-418.
19. Xu, K., Chan, T.C.Y., Vajpayee, R.B. & Jhanji, V. 2015, "Corneal Collagen Cross-linking: A Review of Clinical Applications", *Asia-Pacific Journal of Ophthalmology*, pp. 1.
20. Hayes, S., O'Brart, D.P., Lamdin, L.S., Douth, J., Samaras, K., Marshall, J. & Meek, K.M. 2008, "Effect of complete epithelial debridement before riboflavin-ultraviolet-A corneal collagen crosslinking therapy", *Journal of Cataract & Refractive Surgery*, vol. 34, no. 4, pp. 657-661.
21. Tao, X., Yu, H., Zhang, Y., Li, Z., Jhanji, V., Ni, S., Wang, Y. & Mu, G. 2013, "Role of Corneal Epithelium in Riboflavin/Ultraviolet-A Mediated Corneal Cross-Linking Treatment in Rabbit Eyes", *BioMed Research International*, vol. 2013, pp. 1-6.
22. Bottós, K.M., Schor, P., Dreyfuss, J.L., Nader, H.B. & Chamon, W. 2011, "Effect of corneal epithelium on ultraviolet-A and riboflavin absorption", *Arquivos Brasileiros de Oftalmologia*, vol. 74, no. 5, pp. 348-351.
23. Wollensak, G. & Iomdina, E. 2009, "Biomechanical and histological changes after corneal crosslinking with and without epithelial debridement", *Journal of Cataract & Refractive Surgery*, vol. 35, no. 3, pp. 540-546.
24. Tomita, M., Mita, M. & Huseynova, T. 2014, "Accelerated versus conventional corneal collagen crosslinking", *Journal of Cataract & Refractive Surgery*, vol. 40, no. 6, pp. 1013-1020.
25. Iseli, H.P., Thiel, M.A., Hafezi, F., Kampmeier, J. & Seiler, T. 2008, "Ultraviolet A/Riboflavin Corneal Cross-linking for Infectious Keratitis Associated With Corneal Melts", *Cornea*, vol. 27, no. 5, pp. 590-594.
26. Muller L, Thiel MA, Kiper-Kauer AI et al. Corneal cross-linking as supplementary treatment option in melting keratitis: a case series. *Klin Monbl Augenheilkd* 2012;229:411-5.
27. Makdoui M, Mortensen J, Crafoord S. Infectious keratitis treated with corneal crosslinking. *Cornea* 2010;29:1353-8.
28. Kymionis GD, Portaliou DM, Diakonou VF et al. Management of post laser in situ keratomileusis ectasia with simultaneous topography guided photorefractive keratectomy and collagen cross-linking. *Open Ophthalmol J* 2011;5:11-3.
29. Pollhammer, M. & Cursiefen, C. 2009, "Bacterial keratitis early after corneal crosslinking with riboflavin and ultraviolet-A", *Journal of Cataract & Refractive Surgery*, vol. 35, no. 3, pp. 588-589.
30. Rama, P., Di Matteo, E., Matuska, S., Paganoni, G. & Spinelli, A. 2009, "Acanthamoeba keratitis with perforation after corneal crosslinking and bandage contact lens use", *Journal of Cataract & Refractive Surgery*, vol. 35, no. 4, pp. 788-791.
31. Polymicrobial keratitis after a collagen cross-linking procedure with postoperative use of a contact lens]
32. Kymionis, G.D., Portaliou, D.M., Bouzoukis, D.I., Suh, L.H., Pallikaris, A.I., Markomanolakis, M. & Yoo, S.H. 2007, "Herpetic keratitis with iritis after corneal crosslinking with riboflavin and ultraviolet A for keratoconus", *Journal of Cataract & Refractive Surgery*, vol. 33, no. 11, pp. 1982-1984.
33. Pérez-Santonja, J.J., Artola, A., Javaloy, J., Alió, J.L. & Abad, J.L. 2009, "Microbial keratitis after corneal collagen crosslinking", *Journal of Cataract & Refractive Surgery*, vol. 35, no. 6, pp. 1138-1140.
34. Kymionis, G.D., Bouzoukis, D.I., Diakonou, V.F., Portaliou, D.M., Pallikaris, A.I. & Yoo, S.H. 2007, "Diffuse lamellar keratitis after corneal crosslinking in a patient with post-laser in situ keratomileusis corneal ectasia", *Journal of Cataract & Refractive Surgery*, vol. 33, no. 12, pp. 2135-2137.
35. David P S O'Brart 2012, "Corneal Collagen Crosslinking", *Current Medical Literature*, vol. 22, no. 3, pp. 73.
36. Raiskup-Wolf F, Hoyer A, Spoerl E et al. Collagen crosslinking with riboflavin and ultraviolet-A light in keratoconus: longterm results. *J Cataract Refract Surg* 2008;34:796-801.
37. Koller T, Mrochen M, Seiler T. Complication and failure rates after corneal crosslinking. *J Cataract Refract Surg* 2009;35:1358-62.
38. Romppainen, T., Bachmann, L.M., Kaufmann, C., Kniestedt, C., Mrochen, M. & Thiel, M.A. 2007, "Effect of Riboflavin-UVA Induced Collagen Cross-linking on Intraocular Pressure Measurement", *Investigative Ophthalmology & Visual Science*, vol. 48, no. 12, pp. 5494-5498.
39. Kymionis, G.D., Mikropoulos, D.G., Portaliou, D.M., Vouhouragaki, I.C., Kozobolis, V.P. & Konstantis, A.G.P. 2013, "An Overview of Corneal Collagen Cross-Linking (CXL)", *Advances in Therapy*, vol. 30, no. 10, pp. 858-869.
40. Korav G. A New Alternative to Riboflavin/Ultraviolet-A: Collagen Cross-Linking... *Investigative ophthalmology & visual science*, 03/2016, Volume 57, Issue 3