

# CASE STUDY

## Options of refractive surgery

**Mesha Tanna** describes a case study involving a young lawyer who wanted to stop wearing contact lenses due to lifestyle factors, demonstrating the effectiveness of iDesign Intralase Lasik

Refractive eye surgery helps to improve uncorrected vision by overcoming myopia, hyperopia, astigmatism and the near vision loss suffered through presbyopia, thereby reducing dependency on glasses or contact lenses. As such, it is considered as a procedure that improves visual function. Methods mainly include reshaping the cornea or inserting an implant within the eye.

Surgical techniques advancing from radial keratotomy (RK), photorefractive keratectomy (PRK), laser sub-epithelial keratomileusis (Lasek) to laser-assisted in situ keratomileusis (Lasik) has led to the widespread acceptance of laser treatments over the past 25 years. The most commonly performed type of refractive surgery now is Lasik with impressive benefits of a quick procedure, a speedy visual recovery and minimal discomfort, where a highly sophisticated femtosecond laser is used to create a flap from the corneal surface followed by the ablation of a thin layer of underlying tissue with an excimer laser. Removal of stromal tissue in the centre of the cornea corrects myopia through flattening of the surface while in hyperopia, the ablation is applied in the mid-periphery of the stroma steepening the cornea, resulting in the refractive error moving towards emmetropia.

The biomechanic and healing effects of the cornea after a standard ablation profile are factors believed to increase higher order aberrations (HOAs), which in turn can degrade the retinal image quality.<sup>1</sup> Wavefront-guided treatment reduces such HOAs by applying laser from measurements derived from a wavefront sensor and treatment is based on the aberration profile of the individual eye being treated.

Developments in aberrometers<sup>2</sup> and accurate ocular alignment using iris registration, which allows for pupil centroid shift and cyclotorsion,<sup>3</sup> results in safer and improved visual outcomes.

**TABLE 1** Pre-operative findings

	Right Eye	Left Eye
Unaided vision	6/60	6/60
Manifest refraction	-2.75/-0.50x15	-2.75/-0.25x80
Best corrected vision	6/4	6/4
Central corneal thickness (µm)	592	595
Scotopic pupil diameter (mm)	6.0x6.4	5.4x5.7
Keratometry (dioptries)	43.50/44.00@91	43.75/44.00@90
Mean IOP (mmHg)	16	15

Enjoying vision without the need for glasses or contact lenses is becoming increasingly popular. Reasons for contemplating surgery are numerous and include problems with traditional optical correction, such as contact lens intolerance or difficulty playing sports with glasses, long term cost saving and overall convenience.

### CASE HISTORY

A 29-year-old Asian male presented who was interested in undergoing refractive surgery. He was a lawyer working long hours with early morning 6am starts. Hobbies included playing squash, running and swimming. For all these activities he wore contact lenses. He began to wear glasses from the age of seven and monthly disposable contact lenses from age 17 switching to daily disposable contact lenses at 24. Wear regime was typically six to seven days per week averaging 15 to 17 hours per day. Insertion in the early hours of the morning would often leave his eyes sore by the end of the day.

He had several reasons for seriously considering refractive surgery: convenience for sports and leading an active work schedule, plus the avoidance of the hassle involved in packing contact lenses and solutions when travelling. He was not keen on the use of spectacles.

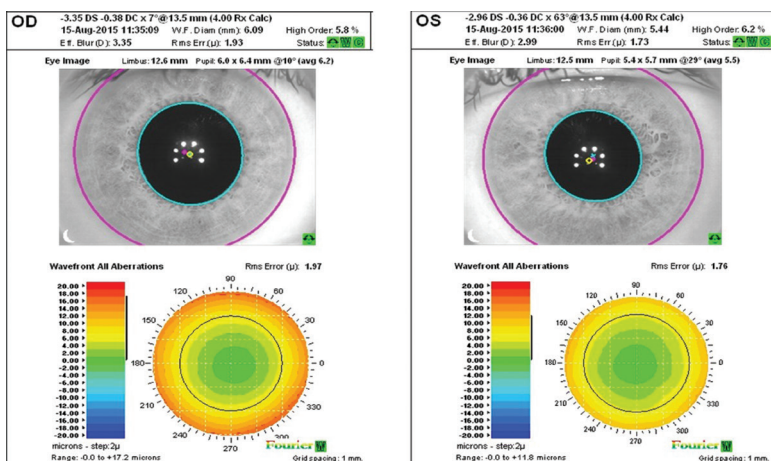
His medical history was unremarkable. Ocular history included two incidences of conjunctivitis unrelated to contact lens wear with the last report two years previously and there was no family history of any eye conditions. The patient reported no symptoms of dry eyes with or without the use of contact lens wear.

He was a driver experiencing good vision with contact lens wear in all lighting levels and suffered from no symptoms of glare or haloes.

Pre-operative findings are included in Table 1.

A detailed slit lamp examination was performed and the findings were that lids and lashes were clear and healthy, the tear film quality was normal with no staining and TBUT was eight seconds. The conjunctiva and cornea were also clear of any pathology, the anterior chamber angle was open grade 4 and

**FIGURE 1** Pre-operative aberrometry findings



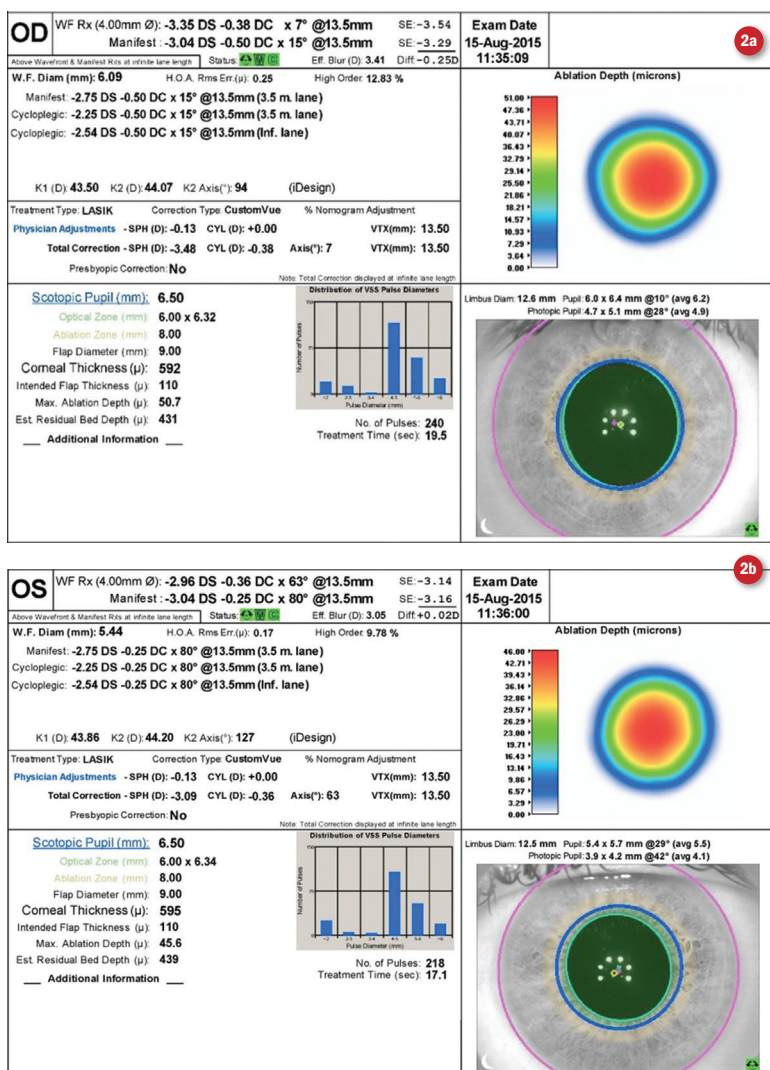


FIGURE 2 Refractive and corneal biometric data preoperative. (2a right eye, 2b left eye)

quiet, the crystalline lens was clear and retinal examination was also normal.

Upon determining the patient's suitability for iDesign Intralase Lasik, the patient completed the early phases of a multi-layered, multi-tiered informed consent process that involved a thorough discussion with his optometrist and the viewing of an 'Informed Consent' video. Both mediums covered the benefits, risks (complications and side effects) and range of visual out-

comes associated with the recommended surgical procedure. A patient information folder containing information on how to prepare for the procedure and what to do and not do afterwards, in addition to copies of an informed consent document were provided.

As a matter of routine, the patient was recommended the opportunity to consult with his treating ophthalmic surgeon ahead of the day of his surgery. The patient elected to meet with his treating ophthalmic surgeon prior to the procedure on the day itself.

Six weeks later, and having met with his treating ophthalmic surgeon prior to the procedure, the patient underwent bilateral iDesign Intralase Lasik. Surgery was routine and uneventful.

## RESULTS

The results are summarised in Table 2.

Clinical examination revealed excellent uncorrected vision which improved from binocular 6/6 to 6/4 over the first few days after treatment. Slit lamp biomicroscopy showed the conjunctiva was clear and the cornea was healthy. The flap made by femtosecond Intralase iFS150 laser was centred well and the interface was clear with no evidence of striae and diffuse lamellar keratitis.

The patient reported at day one: 'operation was pain-free and far quicker than expected... saw results immediately... have no issue following surgery and eyesight is fantastic.'

The patient continued the use of antibiotics and corticosteroids for one week and was walked through advice again on eye hygiene and the return to normal activities which included work, driving and sports.

## DISCUSSION

The patient's motivation for desiring refractive surgery was convenience for sports, enjoying vision without the use of prescription spectacles or contact lenses and relieving the discomfort he had with contact lenses. With post-operative vision of monocular 6/4, all of the patient's requirements have been met.

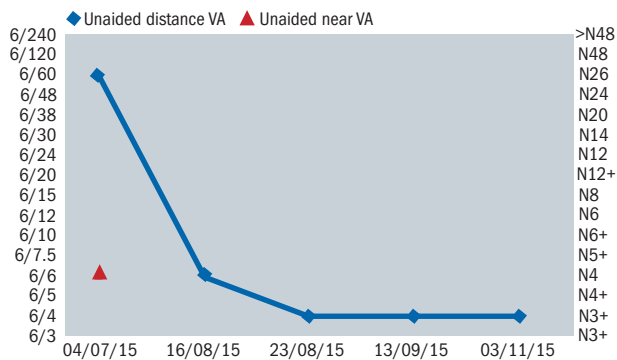
Improper storage of contact lenses and contact lens contact with water and use in swimming pools is not recommended. An organism called acanthamoeba existing in almost all environments causes acanthamoeba keratitis and 90%<sup>4</sup> to 95%<sup>5</sup> of affected individuals tend to be contact lens wearers.

Incidence of bacterial keratitis and acanthamoeba keratitis was found to be one in 100 and about one in 1,000 respectively for people who wore daily wear contact lenses for 30 years. It's →

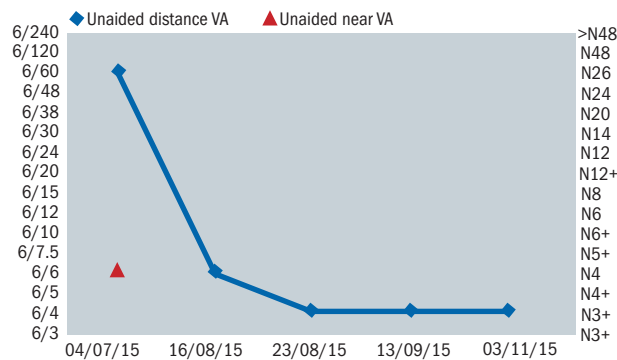
# CASE STUDIES

**TABLE 2 Outcomes post-surgery**

Days Post Surgery	1		8		29		80	
	Right	Left	Right	Left	Right	Left	Right	Left
Eye	Right	Left	Right	Left	Right	Left	Right	Left
BCVA	6/6	6/6	6/4	6/4	6/4	6/4	6/4	6/4
Rx	0	0	+0.25	+0.25	+0.50	+0.25	+0.50/-0.50x5	+0.25/-0.25x160
Keratometry			40.00/40.00 @90	40.25/40.50 @65	40.00/40.25 @90	40.25/40.75 @84	40.00/40.50 @117	40.50/40.75 @80



**Right eye**



**Left eye**

been estimated that some loss of vision in daily contact lens wearers as a result of either infection is one in 2,000, whereas the same risk after Lasik is about one in 10,000 cases.<sup>6</sup> Therefore, the possibility of an infection, and subsequent associated vision loss, is greater in contact lens wearers than with Lasik patients.

The risk of a complication occurring after Lasik is very low. By way of a thorough five-year analysis of outcomes, it has been determined that 0.45% of patients that undergo refractive surgery will develop a complication.<sup>7</sup>

The Hartmann-Shack wavefront sensor of the iDesign system uses AMO Fourier algorithm. By capturing 1,257 points over a 7mm pupil without dilution of any data, the net effect is to measure, map and calculate for highly aberrated corneas and individualising treatment for a broad range of visual imperfections.

Wavefront-guided laser corrects refractive error with excellent visual outcomes safely and effectively. A study of 32,569 eyes with moderate levels of myopia treated with wavefront-guided laser showed the mean manifest spherical equivalent (MSE) reducing from  $-2.97 \pm 1.33$  dioptres (range:  $-0.37$  to  $-6.0D$ ) to  $-0.03 \pm 0.29$  D (range:  $-3.50$  to  $+4.50D$ ) one month after surgery.<sup>8</sup>

Another study, this time treating high myopia over  $-10.00$  dioptres in 332 eyes decreased the mean spherical equivalent by 96%, from  $-11.69 \pm 1.46$  D preoperatively to  $-0.37 \pm 0.80$  D post-operatively and the mean astigmatism decreased 72%, from  $1.66 \pm 1.22$  D to  $0.46 \pm 0.53D$ .<sup>9</sup>

With over 35 million people treated with Lasik by 2010,<sup>10</sup> benefits of the surgical procedure have been received by many professions for which contact lens wear or glasses prove to be a nuisance or unsafe, for example police staff, sports professionals, astronauts, pilots and chefs to name a few.

## CONCLUSION

Lasik refractive technology offers effective and safe outcomes for the improvement of refractive error, presenting alternatives in visual correction to patients. The role of both the optometrist and ophthalmic surgeon is critical in the patient pathway. **Mesha Tanna is clinical director for Optical Express**

## REFERENCES

- 1 Padmanabhan P, Mrochen M, Basuthkar S, Viswanathan D, Joseph R, 2008, 'Wavefront-guided versus wavefront-optimized laser in situ keratomileusis: Contralateral comparative study', *Journal of Cataract & Refractive Surgery*, vol 34, no3, pp 389-397.
- 2 Liu Y, Yeh P, Huang J, Wang I, Chen W, Hu F, Hou Y, 2013, 'Pupil centroid shift and cyclotorsion in bilateral wavefront-guided laser refractive surgery and the correlation between both eyes', *Journal of the Formosan Medical Association = Taiwan yi zhi*, vol 112, no 2, pp 64.
- 3 Schallhorn S, Brown M, Venter J, Teenan D, Hettinger K, Yamamoto H, 2014, 'Early clinical outcomes of wavefront-guided myopic Lasik treatments using a new-generation hartmann-shack aberrometer', *Journal of refractive surgery* (Thorofare, NJ: 1995), vol 30, no 1, pp 14.
- 4 Lonnen J, Putt KS, Kernick ER, Lakkis C, May L, Pugh RB, 2014, 'The efficacy of Acanthamoeba cyst kill and effects upon contact lenses of a novel ultraviolet lens disinfection system', *American Journal of Ophthalmology*, vol 158, no 3, pp 460.
- 5 Stapleton F, Ozkan J, Jalbert I, Holden BA, Petsoglou C, McClellan K, 2009, 'Contact lens-related acanthamoeba keratitis', *Optometry and vision science: official publication of the American Academy of Optometry*, vol 86, no 10, pp E1196.
- 6 Mathers WD, Fraunfelder FW, Rich LF. Risk of Lasik surgery vs contact lenses, *Arch Ophthalmol*, 2006 Oct;124(10):1510-1.
- 7 Venter JA, Hannan SJ, A 'Complex Case Management System Provides Care For All Patients' *Journal of Refractive Surgery*, vol 25, no 7 Suppl, pp S655 – S660.
- 8 Schallhorn SC, Venter JA, 2009, 'One-month outcomes of wavefront-guided Lasik for low to moderate myopia with the VISX STAR S4 laser in 32,569 eyes', *Journal of Refractive Surgery*, vol 25, no 7 Suppl, pp S634.
- 9 Lyle WA, Jin, GJC, 2001, 'Laser in situ keratomileusis with the VISX Star laser for myopia over  $-10.0$  diopters', *Journal of Cataract & Refractive Surgery*, vol 27, no 11, pp 1812-1822.
- 10 Reinstejn DZ, Archer TJ, Gobbe M, 2012, 'The History of Lasik', *Journal of Refractive Surgery*, vol 28, no 4, pp 291-298.